

THE PHARMA RESEARCH

An International Journal of Pharmacy Research

Published on: 15-06-2013

ISSN: 0975-8216

IC Value: 4.36

Impact Factor: 0.536*

Potential Antioxidant and Anti-Inflammatory Effects of Hyphaena thebaica in Experimentally Induced Inflammatory Bowel Disease

Amany shalaby, Ahmed shatta

Affiliation:

Faculty of medicine, Mansoura University, Egypt

ABSTRACT

Aim: Ulcerative colitis and Crohn's disease are chronic recurrent inflammatory bowel disease (IBD) of unknown origin. Oxidative stress is believed to be a key factor in the pathogenesis and perpetuation of the mucosal damage in IBD. The aqueous extract of Hyphaena thebaica fruits showed an antioxidant activity. This study was undertaken to study the effect of Hyphaena thebaica in experimentally induced IBD & to find its probable mechanism of action. Materials and Methods: Sprague Dawely rats were pretreated orally for 5 days with 3% gum acacia in control, Hyphaena thebaica 500 mg/kg in test and 5-aminosalicylic acid (5-ASA) 100 mg/kg in standard groups. Colitis was induced by transrectal administration of 4% acetic acid on 5th day. All the animals were sacrificed with ether overdose 48 hours after colitis induction, and 10 cm colon segment was dissected from proximal end. Colon was weighed (for disease activity index) and scored macroscopically and microscopically after histological staining. Biochemical assessments included myeloperoxidase (MPO) & tissue catalase (CAT), glutathione (GSH) and superoxide dismutase (SOD) measurements.

Results: Hyphaena thebaica showed significant ($P < 0.05$) prevention of increase in colon weight and disease activity index along with decrease in macroscopic and microscopic lesion score as compared to control group. Significant improvement was observed in the levels of MPO, CAT and SOD, except GSH ($P < 0.05$). However, the effect of Hyphaena thebaica was significantly less than 5-ASA ($P < 0.05$). Conclusions: Hyphaena thebaica showed significant amelioration of experimentally induced IBD, which may be attributed to its antioxidant and anti-inflammatory properties.

Keywords: *Colitis, antioxidant, Hyphaena thebaica, myeloperoxidase, catalase, Superoxide*

Introduction: Ulcerative colitis (UC) and Crohn's disease (CD) are two major categories

of inflammatory bowel diseases (IBDs). Although the etiology and pathophysiology of

IBD still remain unclear, immune dysfunction, reactive oxygen species (ROS), inflammatory mediators and cytokines play important roles in its development and recurrence. [1] It is supposed that homeostasis is disrupted in IBD patients because of over-expression of inflammatory cytokines (TNF- α , IL-1, IL-6) and/or lower expression of regulatory or anti-inflammatory cytokines (IL-2, IL-4, IL-10, TGF- β). [1] Common drugs that are administrated for the management of IBD include sulfasalazine, 5-ASA derivatives and glucocorticoids. Immunosuppressants, antibiotics and monoclonal antibodies (Infliximab) are also occasionally used for intractable disease conditions. [2] These therapeutic agents have side effects and they could not appropriately cure IBD patients. [3] In many studies, it has been reported that antioxidants show beneficial effects in experimental colitis. [4]

Medicinal plants and plant products are the oldest and tried health care products. Their importance is growing not only in developing countries but in many developed countries. *Hyphaene thebaica* (L.) mart is one of the plants used in ethnomedicine and belongs to the family palmae and subfamily Borassoideae. It grows commonly in both sahel and sahara regions of Africa. [6]. Locally, various extracts and decoction of *Hyphaene thebaica* are used in the treatment of bilharzia, haematuria, hypertension and as a haematinic agent. [6-8]

Research on the fruit pulp of *H. thebaica* showed that it contains nutritional trace

minerals, proteins and fatty acids, in particular the nutritionally essential linoleic acid. [8] The identification of compounds, by thin-layer chromatography, showed that the fruit contains significant amounts of saponins, coumarins, hydroxycinnamates, essential oils and flavonoids. The fruit also lowers blood pressure in animal models. [9] The aqueous extract of doum fruits showed an antioxidant activity; this is due to the substantial amount of their water-soluble phenolic contents. [10] Acetic acid induced colitis model is similar to human ulcerative colitis in terms of histological features, and has been used extensively in many experimental studies of IBD. [5, 11] The effect of various herbal drugs (but not *Hyphaene thebaica*) on experimental models of IBD has been reported earlier with the antioxidant potential as the main mechanism of action against IBD. [12, 13] As the plant *Hyphaene thebaica* is thought to possess anti-inflammatory and antioxidant properties. [14] This study was undertaken to study the effect of *Hyphaene thebaica* in experimentally induced IBD and to find its probable mechanism of action including its antioxidant potential.

Materials and methods:

Chemicals: All chemicals were purchased from **Sigma chemical company** (St Louis, MO, USA)

Plant material:

The root of *Hyphaene thebaica* (L.) mart was obtained from the plant department of faculty of agriculture, Mansoura University.

Preparation of suspension:

The root of the plant was treated according to the method of Joslyn. [15]. It was dried in an oven for about six hours at 60°C followed by sun drying for days.

The dried root was ground into fine powder using mortar and pestle. The powder was sieved through a 0.25 mm sieve. Aqueous suspension was constituted by dissolving 5g of the powdered root in 100ml of distilled water and stored at low temperature. The suspension was shaken vigorously to obtain a homogenous mixture before administration.

The experiments performed were approved by the Institutional Animal Care and Use Subcommittee of our university.

Twenty-four healthy sprague-Dawely rats weighing 150-200 g were divided into four groups with six animals in each group as follows:

- Group A (normal control) – received 3% gum acacia 10 mL/kg/day, p.o.
- Group B (experimental control) – received 3% gum acacia 10 mL/kg/day, p.o.
- Group C (test) – received *aqueous suspension of pulp extract of Hypphaene thebaica* 500mg/kg/day, p.o. [16]
- Group D (standard) – received 5-ASA 100 mg/kg/day p.o.

The animals were pretreated with the respective drugs (volume of drugs was kept constant at 10 mL/kg) for 5 days, along with the normal diet. On the 5th day, animals were kept fasting for 12 hours (overnight) and IBD was induced next morning in Groups B, C and

D by administration of 1 mL of 4% acetic acid solution transrectally (TR). Group A (normal control) animals received 0.9% normal saline (TR) instead.

For induction of IBD, an 8-mm soft pediatric catheter was advanced 6 cm from the anus under low-dose ether anesthesia. Rats were in Trendelenburg position during this process and 1 mL of 4% acid or 0.9% normal saline solution was slowly administered TR. The rats were maintained in head-down position for 30 seconds to prevent a leakage, and the rest of the solution was aspirated. After this process, 2 mL of phosphate buffer solution with pH 7 was administered (TR). [13]

All the animals were sacrificed after 48 hours of IBD induction, by ether overdose. Abdomen was opened and colons were exposed. Distal 8 cm of colon was excised and opened by a longitudinal incision. After washing the mucosa with saline solution, mucosal injury was assessed macroscopically using the scale of Morris *et al.*[17] as follows: no damage (0); localized hyperemia but no ulceration (1); linear ulcer without significant inflammation (2); linear ulcer with significant inflammation at one site (3); two or more sites of ulceration and inflammation (4) and two or more sites of ulceration and inflammation or one major site of inflammation and ulcer extending >1 cm along the length of colon (5). Disease activity index (DAI) was measured as the ratio of colon weight to body weight, which was used as a parameter to assess the degree of tissue edema and reflects the severity of colonic inflammation. [12]

Moreover, a 6–8 mm sample block of the inflamed colonic tissue with full thickness was excised from a region of grossly visible damage for histological analysis. Formalin fixed tissue samples were embedded in paraffin and stained with Hand E stain. Colonic tissues were scored for histological damage using the criteria of Wallace and Keenan [18]: 0 = intact tissue with no apparent damage; 1 = damage limited to surface epithelium; 2 = focal ulceration limited to mucosa; 3 = focal, transmural inflammation and ulceration; 4 = extensive transmural ulceration and inflammation bordered by normal mucosa; 5 = extensive transmural ulceration and inflammation involving the entire section.

After scoring, the colonic tissue samples were homogenized with 10 volumes of ice-cold 0.25 M sucrose and centrifuged at 14,000 rpm to measure the biochemical parameters in the resulting supernatant.

Biochemical assessments

Myeloperoxidase (MPO) activity: To measure MPO activity, colonic samples were minced on ice and homogenized in 10 ml of ice-cold 50 mM potassium phosphate buffer (pH 6.0) containing 0.5% hexadecyl trimethyl ammonium bromide (HETAB). The homogenates were then sonicated and centrifuged for 20 min at 12,000 g. MPO activity was measured spectrophotometrically as follows: 0.1 mL of supernatant was combined with 2.9 mL of 50 mM phosphate buffer in 0.0005% H₂O₂. The change in absorbance was measured

spectrophotometrically at 460 nm. One unit of MPO activity is defined as the change in absorbance per minute at room temperature, in the final reaction. MPO activity (U/g) = X/weight of the piece of tissue taken, where X = 10 × change in absorbance per minute/volume of supernatant taken in the final reaction. [19]

Assessment of antioxidant status in colonic tissue

Glutathione (GSH) level was determined according to method of Beutler. [20] The reaction mixture contained supernatant, phosphate buffer and 5, 5'-dithio-bis 2-nitrobenzoic acid (DTNB) in a final volume of 10 mL. A blank was also prepared. The absorbance was immediately read spectrophotometrically at 412 nm before and after addition of DTNB. The values were determined from the standard curve.

Superoxide dismutase (SOD) was measured according to the method of Fridovich.[21] Assay medium consisted of 0.01 M phosphate buffer, 3-cyclohexylamino-1-propanesulfonic acid (CAPS), saturated NaOH with pH 10.2, solution of substrate (0.05 mM xanthine, 0.025 mM *P*-iodonitrotetrazolium violet) and 80 μL xanthine oxidase. Absorbance was read spectrophotometrically at 505 nm. SOD was expressed as U/mg of proteins.

Catalase was measured by the method of Beers and Sizer. [22] Phosphate buffer (2.5 mL, pH 7.8) was added to supernatant and incubated at 25°C for 30 min. After transferring into the cuvette, the absorbance was measured at 240 nm

spectrophotometrically. Hydrogen peroxide (650 μ L) was added and change in absorbance was measured for 3 min. Values were expressed as μ mol/min/mg of protein.

Statistical analyses:

Statistical analyses were done using one-way analysis of variance (ANOVA) followed by Dunnett's multiple comparison tests. $P < 0.05$ was considered as significant.

Results:

Acetic acid administration to the experimental control group caused significant macroscopic ulcerations and inflammations ($P < 0.05$) in rat colon along with significant mucosal injury [Figure 2] microscopically ($P < 0.05$), when compared to the normal control group [Figure 1, Table 1] ($P < 0.05$). Also, there was significant derangement of biochemical parameters including tissue levels of MPO, GSH, SOD and catalase ($P < 0.05$), showing oxidative stress due to colon damage and colonic inflammation [Figure 5,6].

Pulp extract of *Hyphaene thebaica* showed significant activity against experimentally induced IBD when compared to the experimental control ($P < 0.05$), with near normalization of colon architecture both macroscopically as well as microscopically [Table 1, Figure 3]. Tissue oxidative stress was reduced with significant improvement in tissue levels of SOD and CAT ($P < 0.05$), showing its antioxidant potential, although there was no significant difference in GSH levels when the two groups were compared ($P > 0.05$). Also, significant improvement in the

levels of MPO was observed ($P < 0.05$) [Table 1, Figure 5, 6].

As for the standard drug 5-ASA, its activity against IBD was significantly better than extract of *Hyphaene thebaica* with regard to all the parameters ($P < 0.05$). When compared to the normal control, 5-ASA s [Table 1, Figures 4], as there was no significant difference between the two groups, i.e., the normal control group and 5-ASA group ($P > 0.05$), thus showing its potent activity against experimentally induced IBD [Figure 5, 6].

Figure 1: Group A (normal control): Normal mucosal architecture

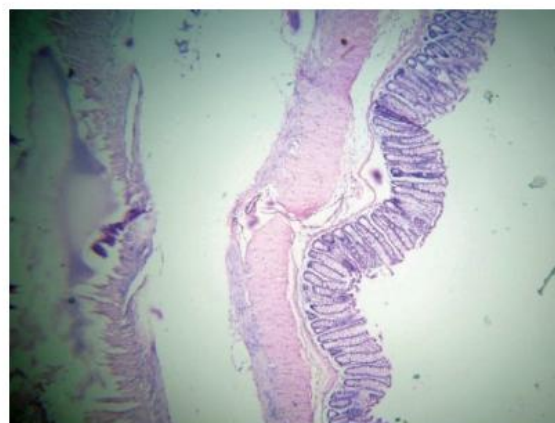


Figure 2: Group B (experimental control): Extensive necrosis with transmural infiltration.

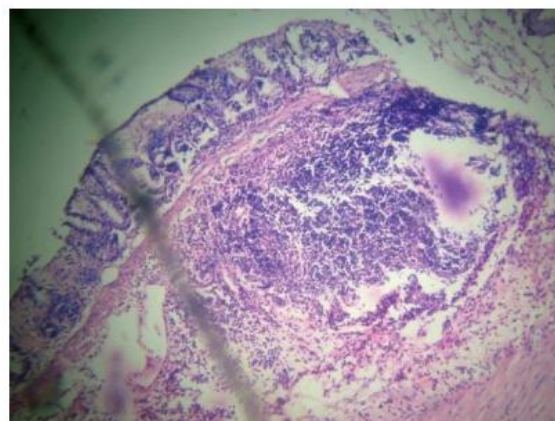


Figure 3: Group C (H.thebaica) Infiltration up to submucosa, architecture maintained.

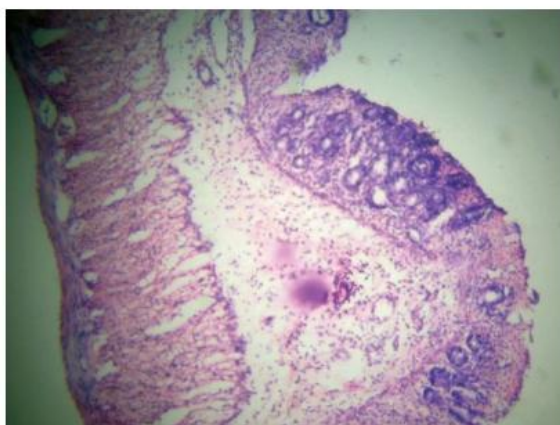


Figure 4: Group D (5-ASA): Near normalization of architecture with mucosal infiltration only.

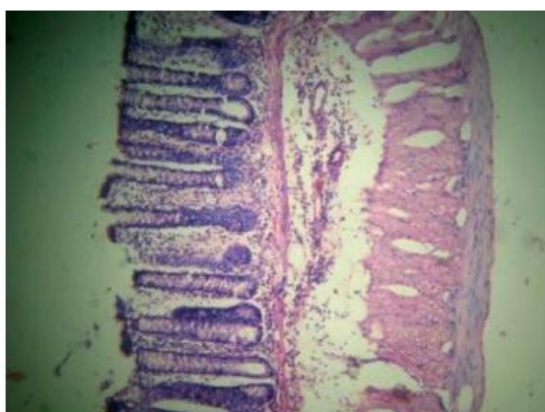


Figure 5: Effect of H.thebaica on tissue CAT (umol/min/mg protein) and GSH (nmol/mg protein) on acetic acid induced colitis in rats. Mean + SE. (6 numbers each)

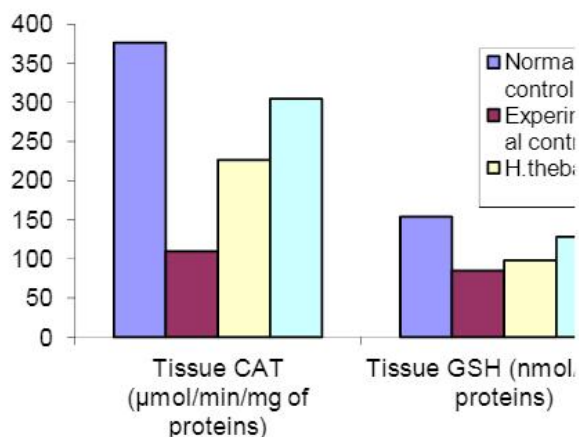


Figure 6: Effect of H.thebaica on tissue SOD (U/mg protein) and MPO (U/g protein) on acetic acid induced colitis in rats. Mean + SE. (6 numbers each)

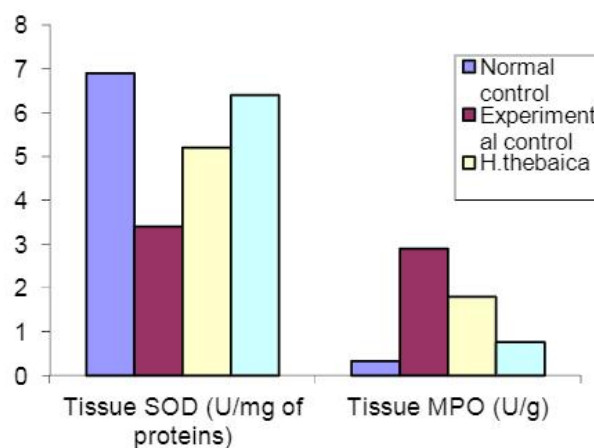


Table 1: Effect of H.Thebaica on Macroscopic Score, Disease Activity Index and Microscopic Score (Mean ± SE)

Groups	Macroscopic score	Disease activity index (DAI)	Microscopic score
Normal control	0.33 ± 0.21	0.67 ± 0.042	0 ± 0
Experimental control	4.67 ± 0.21a	1.14 ± 0.045a	4.7 ± 0.21a
H.thebaica	2.0 ± 0.36a,b	0.9 ± 0.003a,b	3.0 ± 0.36a,b
5-ASA	1.0 ± 0.26a,c	0.76 ± 0.033a,	1.5 ± 0.22a,c
	<0.05	<0.05	<0.05

Value expressed as mean + SE (number 6)

ap :in comparison to normal control

bp: in comparison to experimental control

cp: in comparison to standard group

Discussion:

The results of this study have shown that aqueous extract of *Hyphaena thebaica* has got a good potential to suppress experimental colitis in rats, as indicated by macroscopic, microscopic and biochemical evaluations. Acetic acid induced colitis model is similar to human ulcerative colitis in terms of histological features. It affects the distal colon portion and induces non-transmural inflammation, massive necrosis of mucosal and submucosal layers, mucosal edema, neutrophil infiltration of the mucosa and submucosal ulceration. The protonated form of the acid liberates protons within the intracellular space and causes a massive intracellular acidification resulting in massive epithelial damage. The inflammatory response initiated by acetic acid includes activation of cyclooxygenase and lipoxygenase pathways. [23-24]

The intestinal anti-inflammatory activity of the *H.thebaica* was also related to an inhibitory effect on MPO activity. MPO, an enzyme found predominantly in the azurophilic granules of neutrophils, is a biochemical marker of neutrophil infiltration, and measurements of its activity have been widely used to detect intestinal inflammatory processes. [25, 26] Reduction of MPO activity can be interpreted as a manifestation of the anti-inflammatory property of a given compound. [27]

The flavonoids found in the extract of *Hyphaene thebaica* possess anti-proliferative

activity that causes a decrease in the weight and volume of contents of granuloma in inflammation. [28] Therefore, this might be its probable mechanism of anti-inflammatory action.

Phytochemical studies revealed the presence of flavonoids, coumarins and saponins in *H.thebaica*. Various antioxidant flavonoids and coumarin derivatives have been reported as protective products to prevent and treat intestinal inflammatory processes induced by different chemical inductors of experimental colitis. [29-32] Several studies have shown that different saponins from *Panax ginseng* and *Codonopsis lanceolata* were active compounds in experimental colitis. [33-34] Hence, it is plausible that the presence of these classes of natural compounds in the *H.thebaica* contribute to the observed intestinal anti-inflammatory activity.

Oxidative stress is believed to play a key role in the pathogenesis of IBD-related intestinal damage. [35] Intestinal mucosal damage in the IBD, including Crohn's disease and ulcerative colitis, is related to both increased free radical production and a low concentration of endogenous antioxidant defense. [36]

In the present study the aqueous extract of doum fruits showed an antioxidant activity; this is due to the substantial amount of their water-soluble phenolic contents. [10]

Furthermore, flavonoids are a large group of naturally-occurring plant phenolic compounds that inhibit lipid oxidation by scavenging

radicals or by other mechanisms such as singlet oxygen quenching, metal chelation, and lipoxygenase inhibition. [37]

As proved by the above study and also as described in literature, [14] the extract of *Hyphaene thebaica* possesses significant antioxidant property, proving its role in the management of experimentally induced IBD. Hence, it can be concluded from this study that extract of *Hyphaene thebaica* has potent activity against experimentally induced IBD, due to its anti-inflammatory and antioxidant properties. Further investigations for its clinical utility are warranted.

Acknowledgment:

This study was financially supported from the dept. of clinical pharmacology, faculty of medicine, Mansoura University, Egypt.

Author contribution:

Contribution	Author 1	Author 2
Designed research	+	+
Performed research	+	+
Analyzed data	+	+
Wrote the paper	+	+

References:

- Sellin JH, Pasricha PJ. Pharmacotherapy of inflammatory bowel diseases. In: Brunton LL, Lazo JS, Parker KL, editors. Goodman & Gilman's the pharmacological basis of therapeutics.

- 10th ed. New York: McGraw-Hill companies; 2006. pp. 1009–11.
- Lih-Brody L, Powell SR, Collier KP, Reddy GM, Cerchia R, Kahn E, et al. Increased oxidative stress and decreased antioxidant defenses in mucosa of inflammatory bowel disease. *Dig Dis Sci.* 1996; 41:2078–86.
- McQuaid KR. Drugs used in the treatment of gastrointestinal disease. In: Katzung BG, editor. Basic and clinical pharmacology. 10th ed. New York: McGraw Hill Companies; 2007. pp. 1029–35.
- Cross RK, Lapshin O, Finkelstein J. Patient subjective assessment of drug side effect in inflammatory bowel disease. *J Clin Gastroenterol.* 2008; 42:244–51.
- Nosal’ova V, Cerna S, Bauer V. Effect of N-acetylcysteine on colitis induced by acetic acid in rats. *Gen Pharmacol.* 2000; 35:77–81.
- Von maydell H. Trees and Shrubs of sahel.Their characterstics and uses. Eschborn Germany 1986; pp: 113-175
- Adaya AL, Bdliya H, Bitrus M, Fanjaji D, Eaton MB, Gambo M ,etal. Hidden harvest project.In: Research Series,Compiled by 11ED and HNNCP. 1977; 3(3): 14-27,47-53.
- Kamis AB, Modu S , Zanna H, Oniyangi TA. preliminary biochemical and haematological effects of aqueous suspension of pulp of *Hyphaene thebaica* (L.) mart in rats. *Biochemistri* 2003; 13:1-7.

9. Sharaf A, Sorour A, Gomaa N, Youssef M. Some pharmacological studies on *Hyphaene thebaica*. *Qualitas Plantarium Materiae Vegetables* 1972; 22(1): 83-90.
10. Hsu B, Coupar IM, Ng K. Antioxidant activity of hot water extract from the fruit of the Doum palm, *Hyphaene thebaica*. *Food Chemistry* 2006; 98: 317-328.
11. La JH, Kim TV, Sung TS. Visceral hypersensitivity and altered colonic motility after subsidence of inflammation in a rat model of colitis. *World J Gastroenterol.* 2003;9:2791-5.
12. Ko JK, Lam FY, Cheung AP. Amelioration of experimental colitis by *Astragalus membranaceus* through anti-oxidation and inhibition of adhesion molecule synthesis. *World J Gastroenterol.* 2005; 11:5787-94.
13. Zeytunlu M, Korkut M, Akgün E, Firat O, Aynaci M, İçöz G, et al. The comparative effects of calcium channel blockers in an experimental colitis model in rats. *Turk J Gastroenterol* 2004; 15:243.
14. Mohamed AA, Khalil AA, El-Beltagi HES. Antioxidant and antimicrobial properties of kaff maryam (*Anastatica hierochuntica*) and doum palm (*Hyphaene thebaica*). *GRASAS Y ACEITES* 2010; 61(1): 67-75
15. Joslyn MA. *Methods in Food analysis.* Academic Press Inc., New York .1970; pp: 50-53.
16. Modu S, Kamis AB, Markus PY. Some biochemical effects on aqueous pulp extract of *Hyphaene thebaica* (L.) mart determination in rats. *J Life Environ Sci;* 2001;2/3(1):139-143.
17. Morris GP, Beck PL, Herrigge MS, Depew WT, Szewcdzuk MR, Wallace JL. Hapten induced model of chronic inflammation and ulceration in the rat colon. *Gastroenterology* 1989;96:795-803.
18. Wallace JL, Keenan CM. An orally active inhibitor of leukotriene synthesis accelerates healing in a rat model of colitis. *Am J Physiol* 1990;258:G527-34.
19. Krawisz JE, Sharon P, Stenson WF. Qualitative assay for acute intestinal inflammation based on myeloperoxidase activity. *Gastroenterology* 1984; 87:1344-50.
20. Beutler E. 2nd ed. New York: Grune and Stratton Company; 1975. Red cell metabolism. *A Manual of Biochemical Methods.*
21. Fridovich I. Superoxide radical: An endogenous toxicant. *Annu Rev Pharmacol Toxicol* 1983; 23:239-57.
22. Beers RF, Jr, Sizer IW. A spectrophotometric method for measuring the breakdown of hydrogen peroxide by catalase. *J Biol Chem* 1952; 195:133-40.
23. Sharon P, Stenson WF. Metabolism of arachidonic acid in acetic acid colitis in rats. *Gastroenterology.* 1985; 88:55-63.
24. MacPherson B, Pfeiffer CJ. Experimental colitis. *Digestion.* 1976; 14:424-52.

25. Yamada T, Marshall S, Specian RD, Grisham MB. A comparative study of two models of experimental colitis in rats. *Gastroenterol.* 1992;102:1524–1534.
26. Villegas I, La Casa C, Orjales A, Alarcón de la Lastra C. Effects of dosmalfate, a new cytoprotective agent, on acute and chronic trinitrobenzene sulphonic acid-induced colitis in rats. *Eur J Pharmacol.* 2003;460:209–218.
27. Veljaca M, Lesch CA, Pllana R, Sanchez B, Cham K, Guglietta A. BPC-15 reduces trinitrobenzene sulfonic-induced colonic damage in rats. *J Pharmacol Exp Ther.* 1995;272:417–422.
28. Koganov MM, Dues OV, Tsorin BL. Activities of plant-derived phenols in a fibroblasts cell culture model. *J Natural Products.* 1999;62:481–3.
29. Gálvez J, Sánchez de Medina F, Jimenez J, Zarzuelo A. In: Atta-ur-Rahman (Ed.), *Studies in Natural Products Chemistry.* Rahaman A, editor. Elsevier Science, Amsterdam; 2001. Effects of flavonoids on gastrointestinal disorders; pp. 607–649.
30. Di Stasi LC, Camuesco D, Nietto A, Vilegas W, Zarzuelo A, Gálvez J. Intestinal anti-inflammatory activity of paepalantine, an isocoumarin isolated from capitula of *Paepalanthus bromelioides*, in the trinitrobenzenesulphonic acid model of rat colitis. *Planta Med.* 2004; 70:1–6.
31. Luchini AC, Orsi PR, Cestari SH, Seito LN, Witaicenis A, Pellizzon CH, Di Stasi LC. Intestinal anti-inflammatory activity of coumarin and 4-hydroxycoumarin in the trinitrobenzenesulphonic acid model of rat colitis. *Biol Pharm Bull.* 2008; 31:1343–1350.
32. Witaicenis A, Seito LN, Di Stasi LC. Intestinal anti-inflammatory activity of esculetin and 4-methylesculetin in the trinitrobenzenesulphonic acid model of rat colitis. *Chemico-Biol Interac.* 2010; 186:211–218
33. Joh EA, Lee IA, Jung IH, Kim DH. Ginsenoside Rb1 and its metabolite compound K inhibit IRAK-1 activation – the key step of inflammation. *Biochem Pharmacol.* 2011; 82:278–286.
34. Joh EA, Kim DH. Kalopanaxsaponin A ameliorates experimental colitis in mice by inhibiting IRAK-1 activation in the NF- κ B and MAPK pathways. *Br J Pharmacol.* 2011; 162:1731–1742.
35. Grisham MB, Granger DN. Neutrophil-mediated mucosal injury. Role of reactive oxygen metabolites. *Dig Dis Sci.* 1988;33:6S–15S.
36. Koutroubakis IE, Malliaraki N, Dimoulios PD, Karmiris K, Castanas E, Kouroumalis EA. Decreased total and corrected antioxidant capacity in patients with inflammatory bowel disease. *Dig Dis Sci.* 2004; 49:1433–7.
37. Yanishlieva-Maslarova NV. 2001. Inhibiting oxidation. In: *Antioxidants in Food Practical Applications.* J. Pokorny, N.Yanishlieva and M. Gordon (Ed.), Woodhead Publishing Ltd, Cambridge, pp. 22-70.